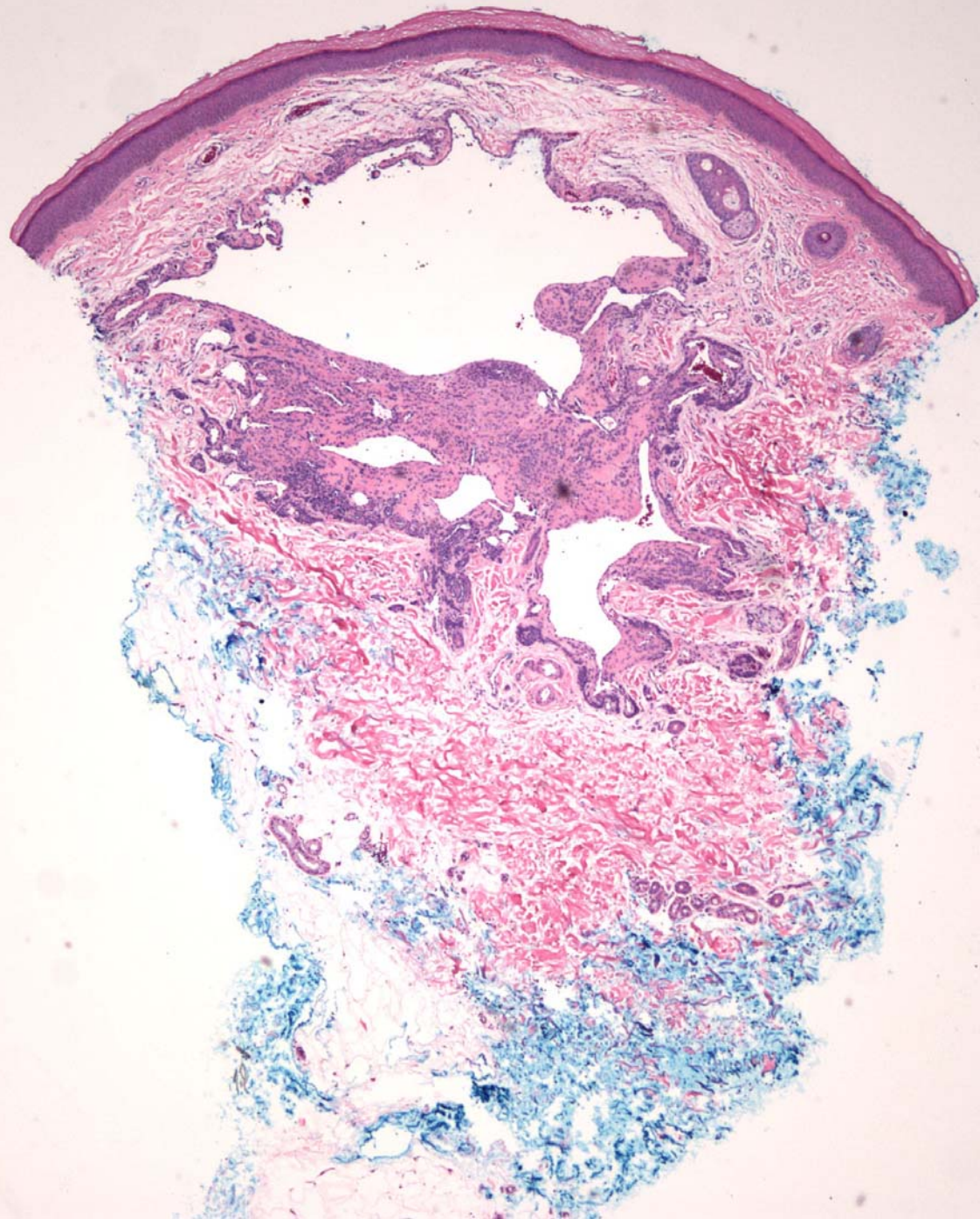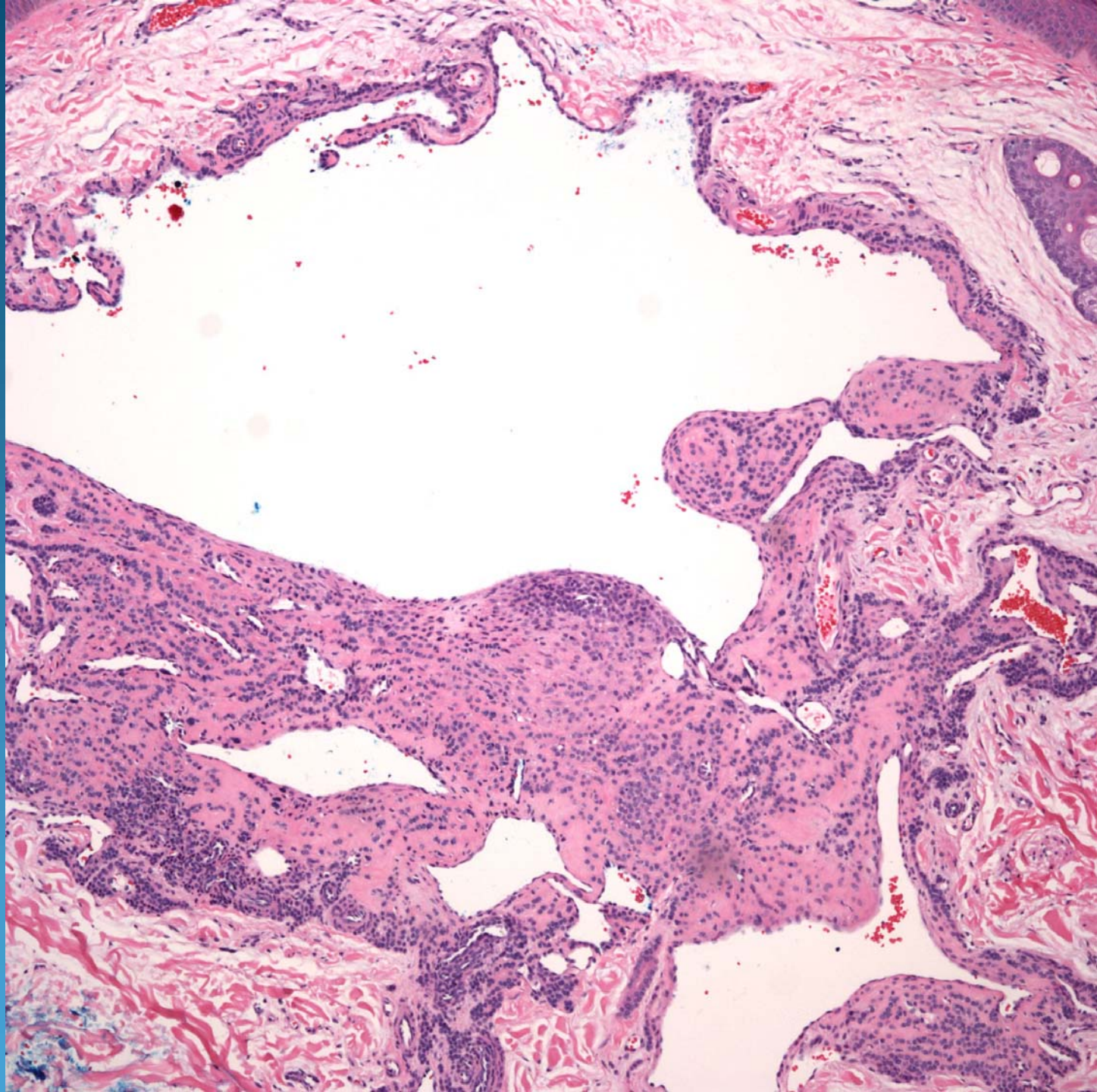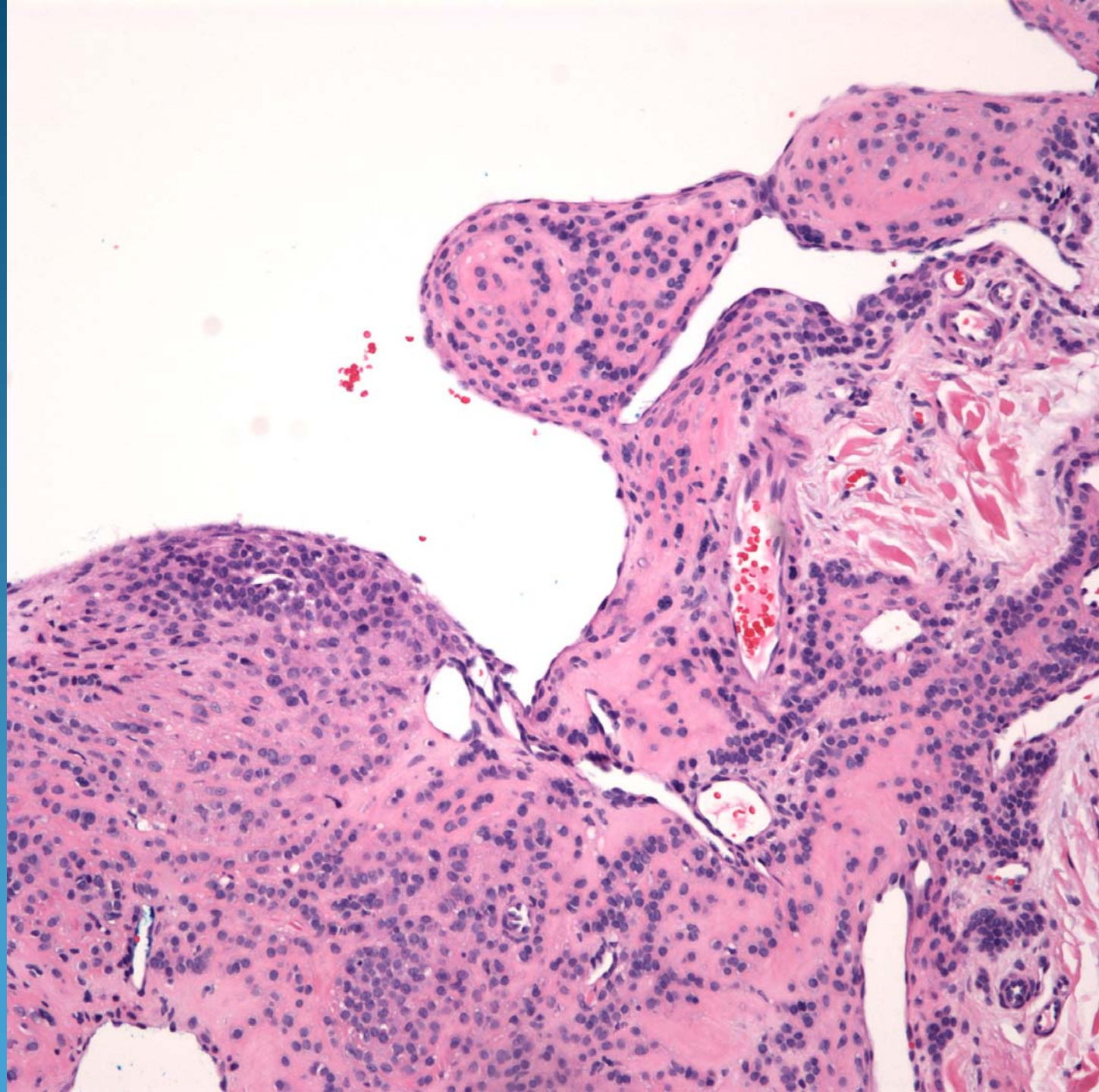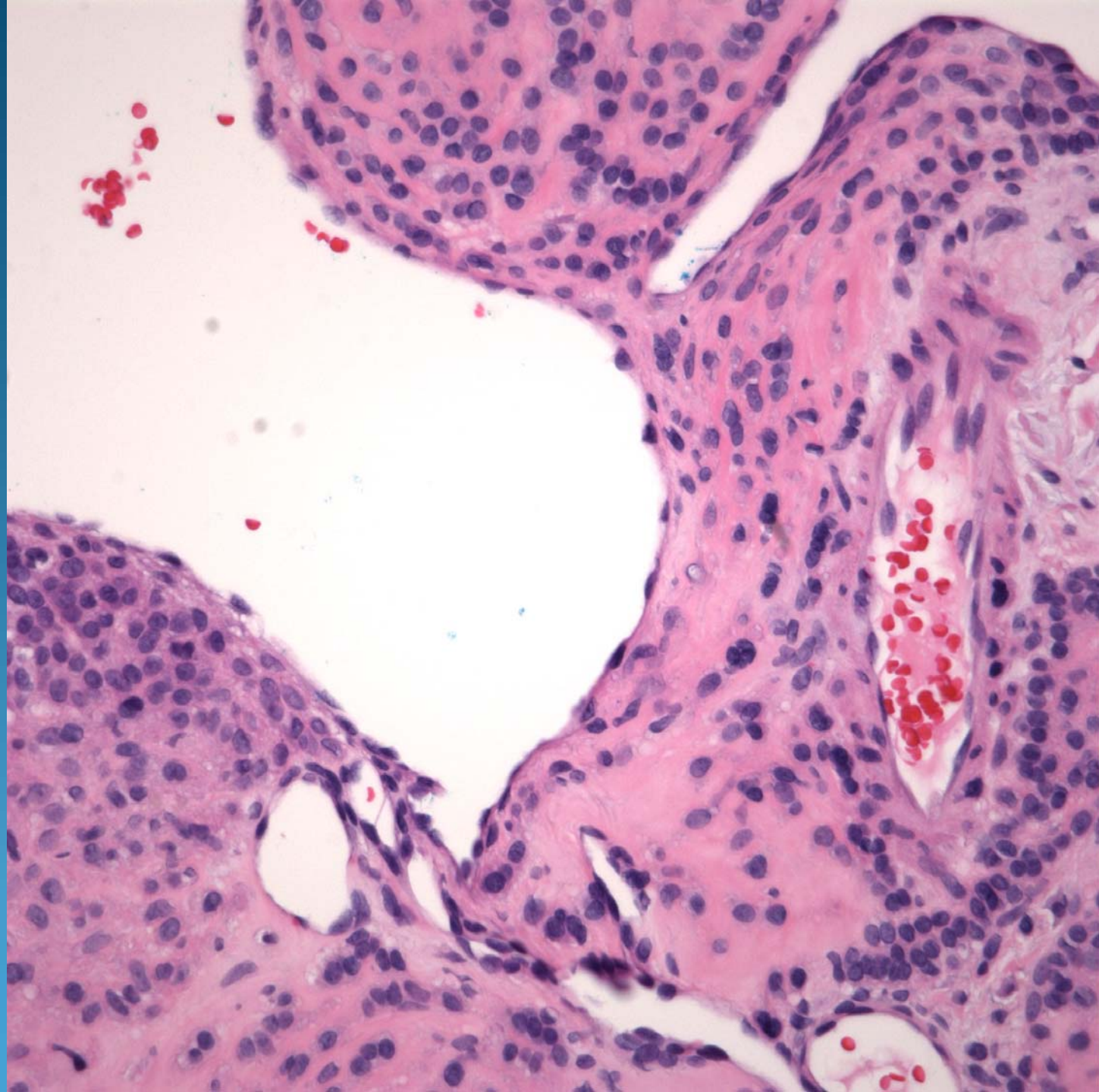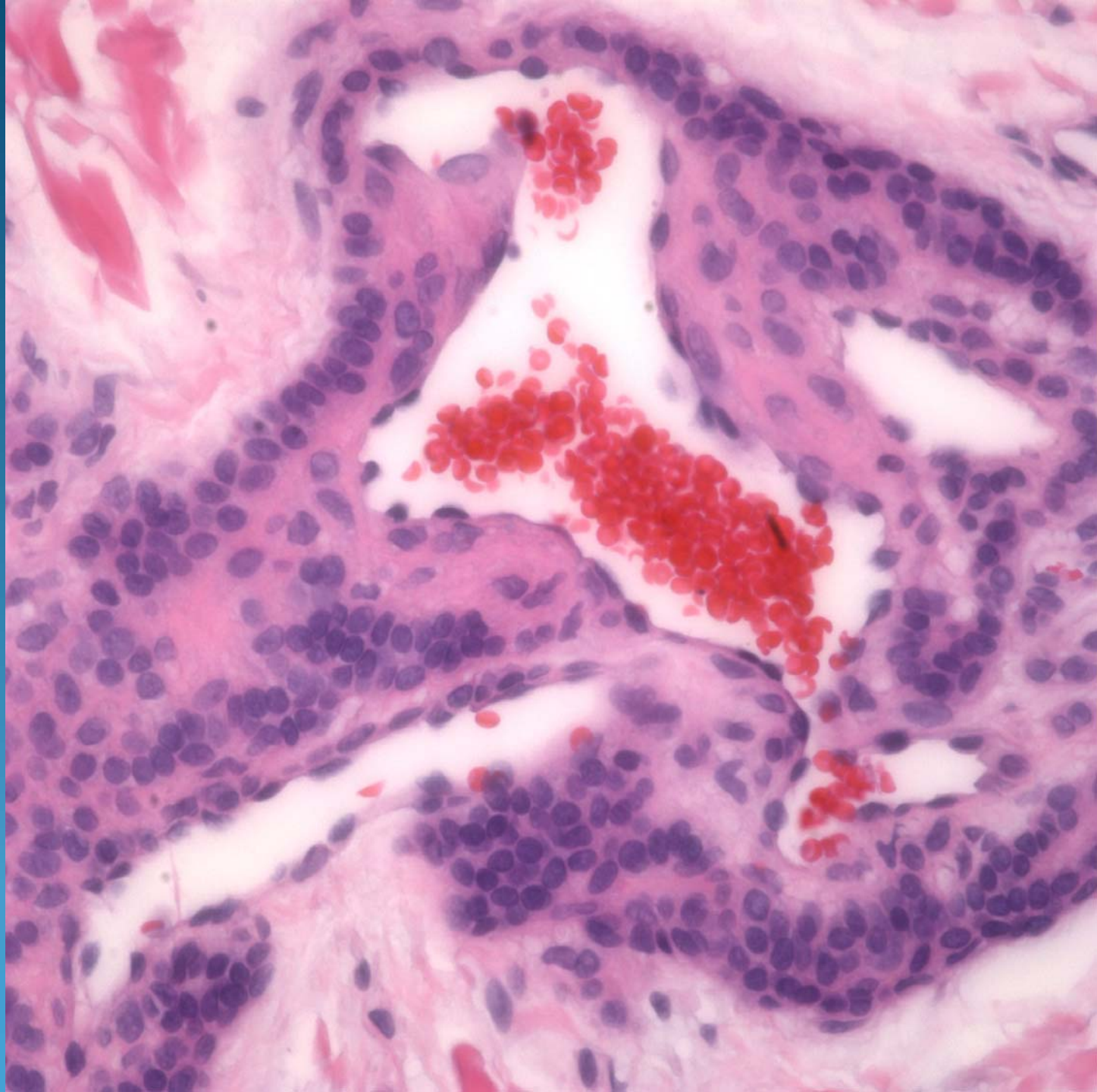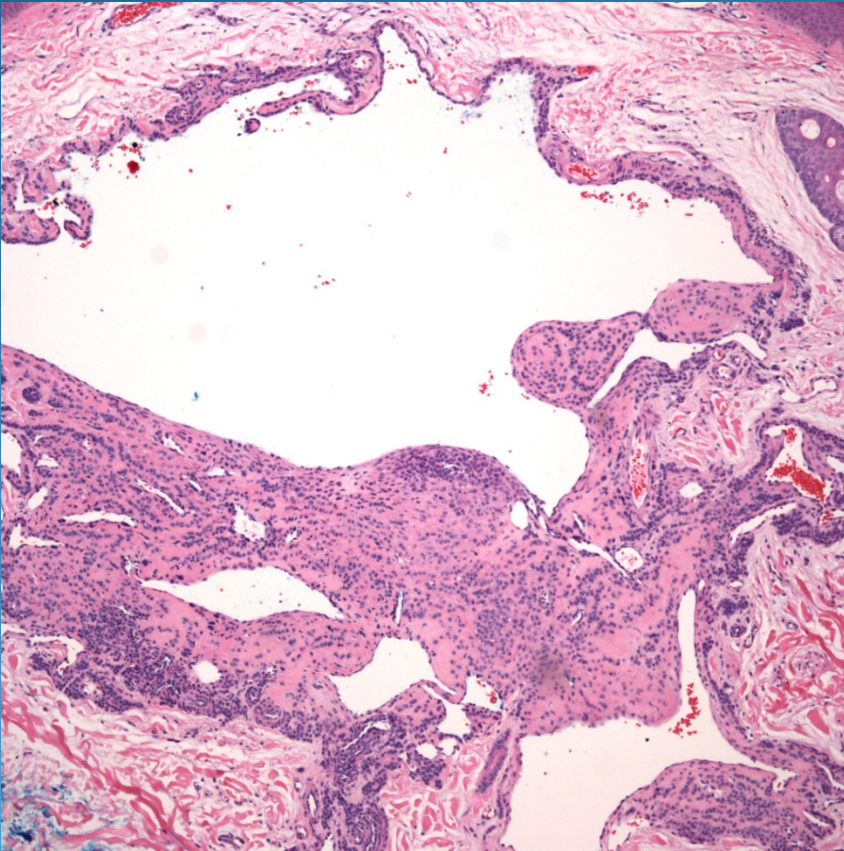


Glomangioma

Pearls



- Ectatic vascular spaces surrounded by glomus cells
- In more cellular lesions, must differentiate from nodular and cystic hidradenoma
- May need IHC-Glomus cells are SMA+, CK-